

Original paper

AN INVESTIGATION ON THE NON SPECIFIC IMMUNE SYSTEM (MUCOSAL) OF TILAPIA (*Oreochromis mosambicus*) BASED ON HISTOCHEMICAL ANALYZES

Ruswahyuni^{1*)}, Pujiono Wahyu Purnomo¹ and Cahyono Purbomartono²

¹⁾ Fisheries Department Faculty of Fisheries and Marine Sciences Diponegoro University,
Jalan Hayam Wuruk 4A Semarang 50241, Indonesia

²⁾ Center of Brackish Water Culture and Research Institution, Jalan Taman Kartini Jepara

Received: May 7, 2003 ; Accepted: June 5, 2003

ABSTRACT

*Mucus is one of a non-specific defense mechanism, since this is the first element of aquatic organisms, which contact physically, chemically, or biologically with the environment. The mucus self defense mechanism investigation was carried out on fresh water fish tilapia (*Oreochromis mosambicus*). Eight (8) types of lectine were used to examine residual carbohydrate-based protein from mucous component based on histological and histochemical observation method. The review was directed as basic information for detail review about physiology adaptation aspects.*

The results showed that mucous in goblet cells from palatal, gills primary lamella, esophagus and skin reacted with WGA (Wheat Germ Agglutinin) lectine. In another part, mucous from the goblet cells in palatal and esophagus cells reacted with PNA (Peanut Agglutinin). Based on these results, therefore, it can be concluded that mucous from goblet cells in esophagus contains residual of N-acetyl glucosamine and/or similar acid β -galactose and α -N-acetyl galactomine. Mucous from goblet cell in palatal contains residual of X-acetyl glucosamine and/or sialat acid and galactose. While mucous in the gills lamella contains carbohydrate residual, namely N-acetyl glucosamine and/or sialat acid.

Key words: Mucus, Tilapia, histochemical analyzes

***) Correspondence:** Telp. 024 – 8311525

INTRODUCTION

Mucous which coats or covers the outer side of fish and other aquatic invertebrate is known as a non-specific mechanical and chemical defense against environmental change and any pathogenous agent. Mucous from each species of fish is different in its physical and chemical natures, and quantitatively, the mucous

production is also different in each species of fish.

Mucous has several functions; many of these are as a mechanical protection, osmoregulation, and barrier to colonization of parasites, fungus and bacteria. Mucous contains several substances, such as immunoglobulin (Rombourt *et al.*, 1995), lysozyme (Fletcher and White, 1973), C-reactive protein (CRP) (Ramos and Smith, 1978)

and lectine (Suzuki, 1995). The main component of mucous is glycoprotein produced by goblet cells/mucous cell (Pickering, 1974). Glycoprotein in mucous varies depends on the fish species. Histochemical painting by lectine at superficial skin tissue showed the existence of glycoprotein mucous in the goblet cells (Asakawa, 1970).

Tilapia (*Oreochromis mosambicus*) is one of fresh water fish that can survive in brackish water or in relative muddy water, and has a good adaptation level and resistance in the unfavorable environment. The investigation was aimed at examining goblet/mucous cells distribution in producing mucous and biochemical nature of lectine in Tilapia.

MATERIALS AND METHODS

Tilapia (*Oreochromis mosambicus*) of 15.2 – 25.0 cm total body lengths and 145 – 250 grams of body weight was used in this experiment.

After anesthesia by 0.01% 2-b-phenoxyethanol, samples from palatal epithelium, gills, esophagus and skin were drawn. These samples were fixed in Bouin liquid for 24 hours at room temperature, and then dehydrated through series of ethanol, infiltrated with paraffin and embedded in hystoparaffin. The embedded tissue was cutted in 5-cm thickness and painted with haemotoxylin-eosin. The tissue observed using microscope.

Histochemical painting was done in which each sample was fixed in 4% paraformaldehyde liquid in 0.1 M phosphate buffer pH 7.2 and stored several

days at temperature at 4° C. These samples were embedded and cut with thickness aforementioned. The lectine was conjugated by FITC (Floresence Immuno Thiocyanat) that was used for histochemical painting. In this test, 8 lectine were used. Painting technique orders were done after deparafination process by xylene continued by dehydration to series ethanol concentrat from 100% to 70%. Sample was washed 3 times in PBS at pH 7.4, and then incubated by FITC-lectine that was diluted by PBS (1: 1000) in room temperature for 1 hour in dark condition, and then washed 3 times by PBS. After the slides were closed by glass object using 1.4 Diazabicyclo (2-2-2) octane solution (Sigma, St. Louis, MO) liquid that mixed with glycerol (1:1) was then observed by florescent microscope. The sample incubated by PBS without FITC-lectine at room temperature for 1 hour was used as a control.

RESULTS AND DISCUSSION

Mucous cell histology

The figures of mucous cell histology from several tissues of Tilapia were shown in **Table 1**. The epithelia surface from palatal cells of Tilapia (**Figure 1a**) indicates many goblet/mucous cells in different shapes and sizes. Several mucous found in this area has cylindrical shape, but no broken cells in proximal were found. The mucous cells density was approximately 47 cells / 0.01 mm², and the biggest mucous cell size was 60 µm height and 40 µm widths.

Table 1. The figures of mucous cell histology from several tissues of Tilapia

No	Variable	Palatal epithelium	Gills	Esophagus	Skin
1	Type	Oval, ellipse	Globular, small	Oval, ellipse	Oval
2	Biggest size (µm)	Height 60, width 40	Diameter 10	Height 70, width 50	Small
3	Total (0,01 mm ³)	47	12	23	4

In the gills (**Figure 1b**), mucous cells were relatively low and distributed at apical area. Several cells contain mucous in vesicle shape and swell to oval cells. These mucous cells were relatively small in their shape at the diameter of about 10 μm . The number of mucous cells approximately 12 cells / 001 mm^2 .

In esophagus (**Figure 1c**), the epidermis was constructed by cells layer in cuboids shape. In this area, the mucous cells were well developed and varied in their shape, from circle to oval. Mucous cells density about 23 cells / 0.01 mm^2 , and the biggest cell was 70 μm height and 50 μm width respectively.

Many mucous cells were found in palatal epitheliums cell and esophagus. According to Drenner *et al* (1984), tilapia

(*Oreochromis esculeritus*) was reported as a type of “size-selective suspension feeder” fish and the mucous that disposed from digestion duct was related to feeding digestion activity. Furthermore, Sanderson *et al* (1996) reported that in Tilapia (*Oreochromis niloticus*) the mucous secretion speed was determined by stimulus response toward particle size of feed.

A thin layer from several epithelia cells built the skin epidermis of tilapia (**Figure 1d**). The epidermis surface was relatively smooth in its shape covered by several epithelia squamous cells. The number of mucous cells was relatively small, i.e. about 4 cells / 0.01 mm^2 which were distributed on the surface of epidermis layers.

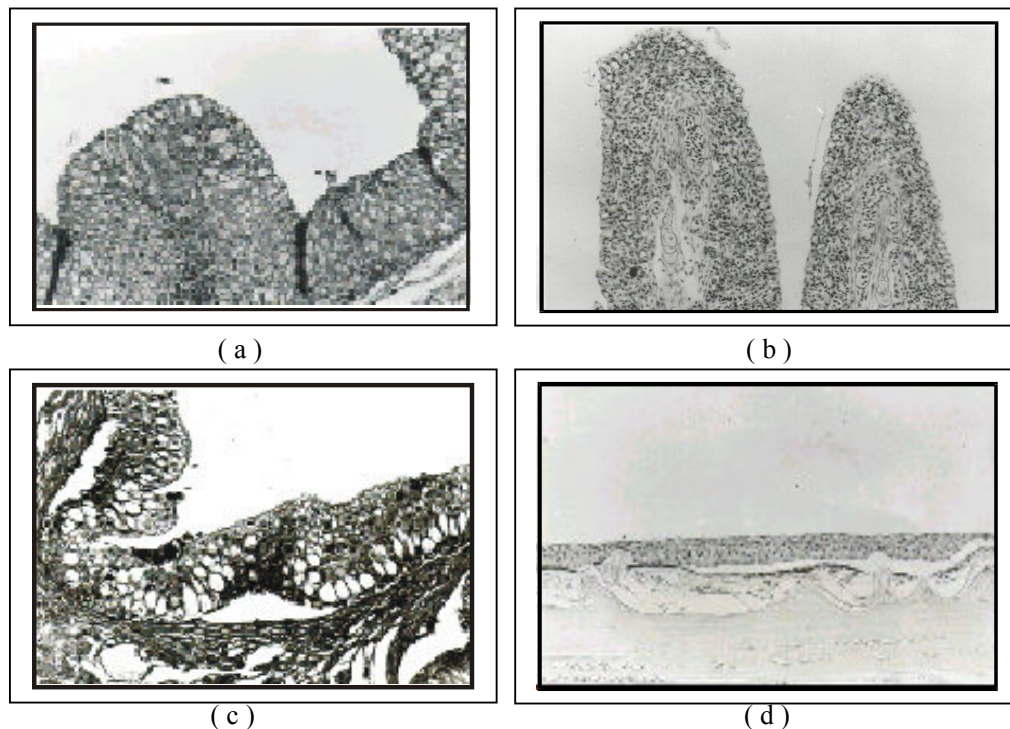


Fig. 1. Observation histological from several tissues of Tillapia (*Oreochromis mosambicus*)

- a. Goblet cell epithelium from palatal
- b. Goblet cell from gills
- c. Goblet cell from esophagus
- d. Goblet cell from skin

Histochemical of goblet/mucous cells

From 8 types of lectine used in the test (**Table 2**), WGA (Wheat Germ Aglutinine) reacted with epithelium of palatal cells, gills primary lamella, esophagus and skin of Tilapia. Lectine of PNA (Peanut Aglutinine) type reacted with surface of palatal epithelium and esophagus cells. Lectine from DBA (Dilichos Biflofus) type reacted only with esophagus. Painting/reaction intensity shows that WGA was stronger than PNA and DBA toward mucous cells. The other types of lectine such as LCA, RCA, OHA, Con-A and

UEA showed no reaction with mucous cells.

The epithelium cells of palatal, lectine of WGA type was different from PNA such as painting intensity or the number of mucus cells that positively reacted (**Figure 2**). Lectine of WGA type was stronger in their reaction intensity with mucous cells than PNA. Also lectine of WGA type reacted with mucous cells from the gills, esophagus and skin. Both PNA and DBA lectines weakly reacted with mucous cells from esophagus.

Table 2. Painting FITC-lectine on several tissues of Tillapia

No	Kind of lectine	Palatal epithelium	Gills	Esophagus	Skin
1	WGA	++	++	++	+
2	PNA	+	-	±	-
3	LCA	-	-	-	-
4	RCA	-	-	-	-
5	PHA	-	-	-	-
6	Con-A	-	-	-	-
7	UEA	-	-	-	-
8	DBA	-	-	±	-

Explanation:

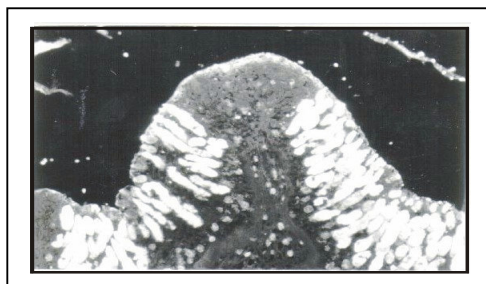
++: Strongly reacted

- : Weakly reacted

± : Fairly reacted

According to Gona (1979) the function of mucous layer was very related to type of glycoprotein produced by mucous cells. Lectine of WGA type was found more in mucous cells in rat, monkey, ma, and guinea pig. The lectine

of WGA type was specific to residual of carbohydrate N-acetyl glucosamine and sialat acid. These meant that residual of protein-based carbohydrate was found more in this tested tilapia.



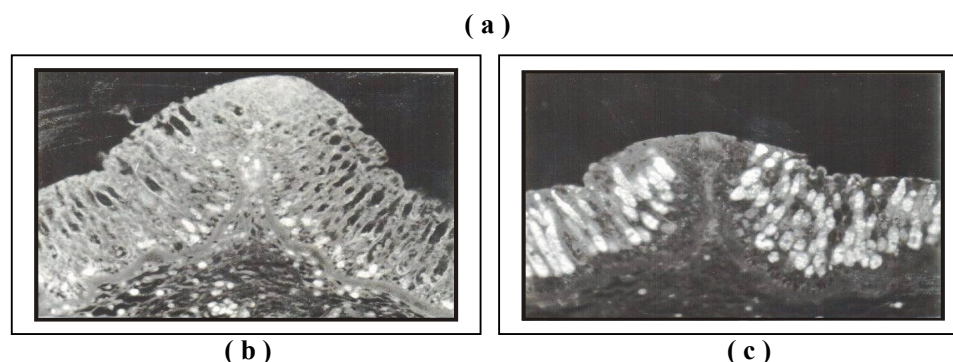


Fig. 2. Observation of FITC-lectine on epithelium palatal cell from *Tilapia*
a) Epithelium cells from palatal positive reaction with WGA. Goblet cells strong reaction with WGA (arrow);
b) Epithelia cells positive reaction with PNA. Painting intensity is not strong with WGA (arrow);
c) Epithelia cells of palatal as control. No reaction with goblet cells (arrow).

Lectine of PNA type found in mucous cells of *Tilapia* intestine according to Pajak and Danguy (1993) was contained residual of b-galactose and β -N-acetylgalactosamine that plays as a viscoelastic barrier that covers mucous from acid and proteolyses environment. Lectine of DBA type was also found in mucous cells of intestine according to Menghi *et al* (1996), lectine of DBA type was generally found in epithelium and glandule of tilapia's side, frog and turtle intestine.

CONCLUSION

1. The mucous cells in tilapia were found in palatal cells, gill primary lamellae and esophagus or skin.
2. Lectine of WGA type was found in mucous cells from palatal cells, gill primary lamella, esophagus and skin. Lectine of PNA and DBA types were

found only in mucous cells from tilapia's esophagus.

REFERENCES

- Asakawa, M, 1970. Histochemical studies of the mucus on the epidermis of eel, *Anguilla japonica*. *Nippon Suisan Gakkaishi*. 36: 83-87.
- Drenner, R.W, Taylor, S.B., Lazzaro, X. and Kettle, D. (1984). Particle-grazing and plankton community impact of an omnivorous cichlid. *Trans. Am. Fish. Soc.* 113: 397-402.
- Fletcher, T.C. and White, 1973. Lysozyme activity in the plaice (*Pleuronectes platessa L.*). *Experientia* 29: 1283-1285.

- Gona, O. 1979. Mucus glikoproteins of teleostean fish, a comparative histochemical study. *J. Histochem.* 11: 709-718.
- Menghi, G., Scocco, P. and Ceccarelli, P. 1996. Glycohistochemistry of the tilapia spp stomach. *J. Fish Biol.* 49: 584-593.
- Pajak, B. and Danguy, A. 1993. Characterization of sugar moieties and oligosaccharides sequences in the distal intestinal epithelium of the rainbow trout by means of lectine histochemistry. *J. Fish Biol.* 43: 709-722.
- Pickering A.D. 1974. The distribution of mucous cells in the epidermis of the brown trout (*Salmo trutta L.*) and the char (*Salvelinus alpinus L.*). *J. Fish Biol.* 6: 111-118.
- Ramos and Smith, A.C. 1978. The-C-reactive protein (CRP) test for the detection of early disease in fishes. *Aquaculture* 14: 261-266.
- Rombout, J.H.W.M., N. Taverne, M. van de kamp and A.J. Taverne-Thiele., 1995. Differences in mucus and serum immunoglobulin of carp (*Cyprinus carpio L.*). *Dev. Comp. Immunol.* 17: 309-317.
- Sanderson, S.L., Stebar, M.C., Ackermann, K.L., Jones, S.H., Batjakas, I.E. and Kaufman, L., 1996. Mucus entrapment of particles by a suspension feeding tilapia (Pisces: Cichlidae). *J. Exp. Biol.* 199: 1743-1756.
- Suzuki, Y., 1995. Defense mechanisms in the skin of fish. In: Defense mechanisms in aquatic animals (ed. K. Mori and H. Kamiya), pp. 9-17, *Koseisyu Koseikaku, Tokyo.*