

Anesthesia Management on 29 Weeks Pregnant Women with Intracranial SOL, Invasive Carcinoma Mammae and Bronchopneumoniae

Dina Paramita^{✉*}, Irfani Kurniawan^{**}

*Department of Anesthesiology and Intensive Therapy, Faculty of Medicine, Diponegoro University/RSUP Dr. Kariadi, Semarang, Indonesia

**Faculty of Medicine, Diponegoro University, Semarang, Indonesia

✉Correspondence: Dinaparamita6@yahoo.com

ABSTRACT

Background: Pregnancy gives whole different challenge for anesthesiologist because of we handle two lives at once. Brain tumor in pregnancy correlated with maternal mortality, prematurity and intra uterine growth restriction (IUGR). It makes delivery time, what kind of anesthesia technique we used chosen by the situation.

Case: We report a case of anesthesia technique using general anesthesia (GA) to accommodate sectio cesarean transperitoneal profunda (SCTP) in a 29 weeks pregnancy age, G1P0A0 female patient, ASA IIIIE with intracranial SOL suspect cerebri abscess multiple dd/ tuberculoma, invasive mammae carcinoma, and bronchopneumoniae.

Discussion: Space occupied lesion (SOL) is a lesion in intracranial space especially give effect to brain. In our patient with SOL from cerebri abscess multiple dd/ tuberculoma. It caused intracranial pressure increase and also spastic hemiparese dextra. Pregnancy termination was done depends on 29 weeks pregnancy with SOL in this patient. We used GA for cesarean section (CS). Anesthesia technique will be considered successful if new born baby activity, pulse, grimace, appearance, and respiration (APGAR) is good.

Conclusion: Female G1P0A0, 32 years old, 29 weeks pregnancy age, single intrauterine fetus with intracranial SOL suspect cerebri abscess multiple dd/ tuberculoma, invasive mammae carcinoma, and bronchopneumoniae was consulted by Obstetrician to Anesthesiologist to do CS with GA. During anesthesia and surgery, there was no complication. In this case, termination was done for baby and mother's well being.

Keywords: cesarean section; general anesthesia; intracranial SOL; pregnancy; SCTP

INTRODUCTION

Pregnancy has an impact on anatomical, physiological, pharmacological and psychological changes in the mother so that caesarean section in pregnant women is a challenge for anesthesiology specialists, because of considerations for the safety of the mother and baby.¹

Brain tumors in pregnancy are correlated with increased maternal mortality, premature birth and intrauterine growth restriction (IUGR).² The presence of a brain tumor in pregnancy will influence the determination of the time of delivery, the type and technique of anesthesia to be used. About 75% of intracranial tumors occur in women of reproductive age and during pregnancy. Tumor enlargement during pregnancy is related to fluid retention, accumulation of hormonal changes, swelling of blood vessels, and the presence of growth hormone receptors which cause progression of neurological symptoms during pregnancy and post-partum remission.³

Mothers with intracranial lesions are often assumed to have increased

intracranial pressure, even in the absence of clinical and radiographic signs. To care for these women and determine which of them can safely undergo spinal or epidural analgesia or anesthesia we must understand the factors involved. contribute to clinically significant shifts in brain tissue (i.e. brain herniation), such as increased intracranial pressure (ICP), brain edema, or hydrocephalus. The anesthesiologist can then effectively weigh the relative risks and benefits of neuraxial anesthesia.⁴

Intracranial space occupying lesion (SOL)

Space occupying lesion (SOL) is a generalization of lesions in the intracranial space, especially those affecting the brain. SOL is caused by the presence of a new mass in the cranium which is generally associated with malignancy but can also be caused by other pathological conditions such as brain abscess or hematoma.⁴ This mass produces consequences in the form of increased intracranial pressure because the cranium is a space with a fixed volume.^{1,2,3}

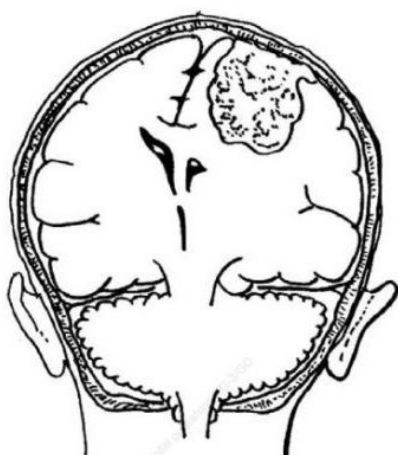

Figure 1. Schematic of the spatial compression process with a perifocal effect that causes compression of brain tissue and midline shift.³

Etiology of space occupying lesion (SOL)

There are several causes that can cause brain SOL, including: (1) neoplasm: primary or metastatic; (2) inflammatory causes: abscess, tuberculoma, syphilitic gum, fungal granuloma; (3) parasitic infections: cysticercosis, hydrated cyst, abscessamoeba, schistosoma japonicum; (4) traumatic brain injury: subdural & extradural hematoma; (5) congenital causes: dermoid, epidermoid, teratoma.⁴

Intracranial anatomy

The brain consists of 3 main structural divisions: the cerebrum, brainstem, and cerebellum (Figure 2). At the base of the brain is the brainstem, which extends from the upper cervical spinal cord to the diencephalon of the cerebrum. The brainstem is divided into the medulla, pons, and midbrain. Behind the brain stem lies the cerebellum. The meninges consist of 3 layers of tissue that cover the brain and spinal cord: the pia, arachnoid, and dura mater (Figure 3). The pia together with the arachnoid are referred

to as leptomeninges, while the dura is referred to as pachymeninx.⁵

The cellular structure of the brain mainly consists of neurons and their supporting cells, which are broadly called glial cells. The 3 main types of glial cells are astrocytes, oligodendrocytes, and microglia. These glial cells can give rise to glial tumors, such as astrocytoma, oligodendroglioma, and glioblastoma, which are among the most common primary brain tumors.⁵

The Monro-Kellie doctrine is currently used as a reference in measuring intracranial pressure. Intracranial content consists of brain tissue, blood and cerebrospinal fluid. If in a situation there is an increase in intracranial mass, the initial compensation is a decrease in the volume of venous blood and cerebrospinal fluid (CSF). The next compensation is that the CSF will be pushed through the foramen magnum towards the spinal subarachnoid cavity.⁵

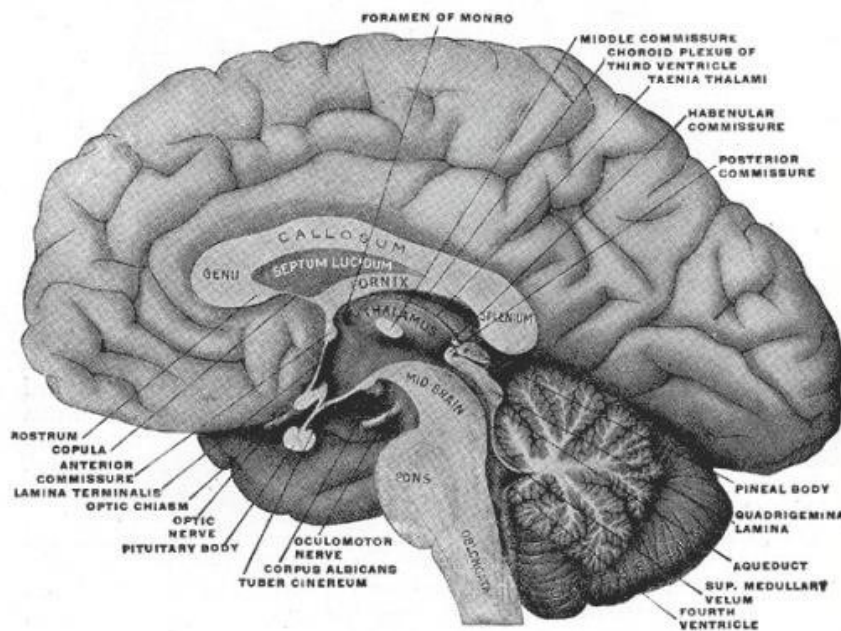


Figure 2. Brain anatomy⁵

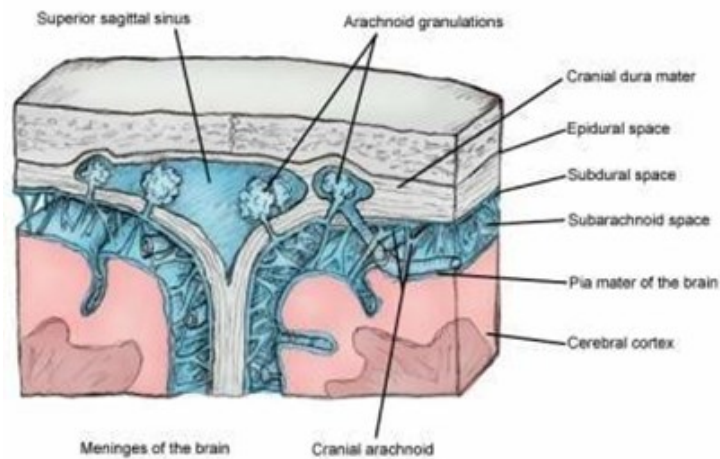


Figure 3. Meninges layer⁵

Clinical features of intracranial SOL

The common manifestation of SOL is headache and is the worst symptom in about half of the patients. Headache is a dull, constant pain, sometimes throbbing.⁶

Diagnosis of intracranial SOL

The diagnosis of SOL is made with an appropriate history, relevant examination findings, and appropriate supporting examinations. Advances in cranial imaging have made the detection of intracranial lesions relatively accurate and allowed us to focus on the etiology of the lesions occupying this space.⁶ X-rays of the skull and brain provide only limited insight into brain tumors. Computerized tomography (CT) scan of the head or magnetic resonance imaging (MRI) of the head to confirm the

presence of a tumor and the location of the tumor. MRI is more sensitive for detecting small metastatic tumors. Imaging is important to determine whether it is a true tumor or shows the appearance of an abscess. An abscess is differentiated from a tumor by the presence of enhancement on a CT scan with contrast. It may be difficult to differentiate pyogenic brain abscess from necrotic glioblastoma and cystic metastases with conventional MRI because all can appear as rim-enhancing masses with prominent perifocal edema.^{7,8} Diffusion-weighted imaging (DWI) and diffusion-tensor imaging (DTI) are measuring water diffusivity complements the role of conventional MR in the differentiation of abscesses from glioblastoma and necrotic metastases.^{6,7,9}

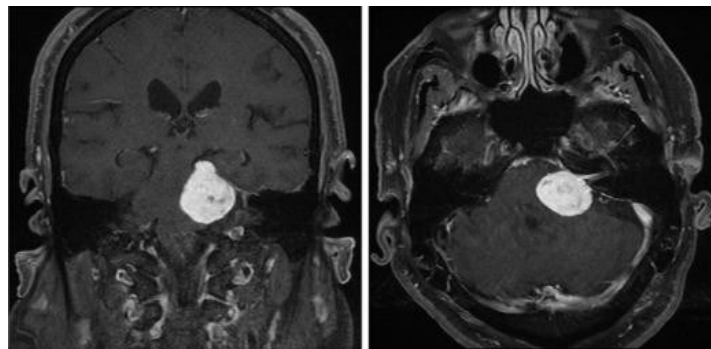


Figure 4. Meningioma with MRI⁸

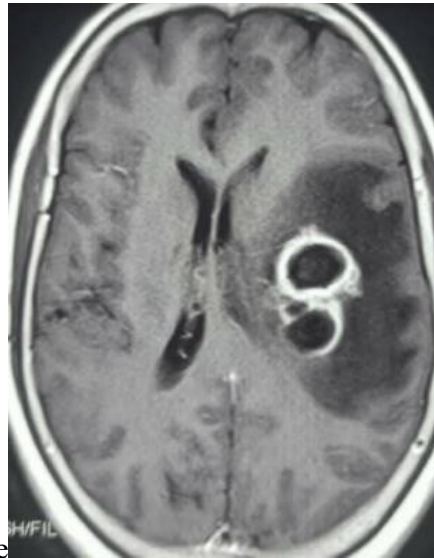


Figure 5. Cerebral abscess with CT Scan⁹

Management of intracranial SOL

Some intracranial tumors are not amenable to surgical resection, or the characteristics of such lesions make them more appropriate to treat with radiation therapy. For example, if the lesion is small, or is in several parts of the brain, or within an area of the brain where surgical resection could potentially cause more harm than good, radiation therapy is a consideration. Consultation with a radiation oncologist can provide patients with a variety of radiotherapy treatment options to target the tumor. For example, patients with multiple diffuse metastases too numerous for surgical resection may benefit from whole brain radiation therapy, whereas patients with single small radiosensitive lesions may benefit from stereotactic radiosurgery. Patients who also undergo surgical resection of their intracranial tumors often receive radiation therapy to the surgical resection bed.⁸

Chemotherapy is also used as a therapy for some tumors. A consultation with a neuro-oncologist should be undertaken, and various chemotherapy regimens should be discussed. Traditionally, the

use of chemotherapy in the brain has been limited, because the nature of the blood-brain barrier limits the efficacy of drugs that cross the barrier.⁸

Cerebral abscesses can be considered for treatment with a medical or surgical approach. Medical management may be considered for small, deep abscesses (less than 2 cm), cases of meningitis, and certain other cases.¹⁰ Typically, a combination of medical and surgical approaches is considered. The choice of antibiotic regimen should be made judiciously based on the microorganisms isolated from the blood or CSF. Certain antibiotics cannot cross the blood-brain barrier and are not useful in treating brain abscesses; These antibiotics include first generation cephalosporins, aminoglycosides, and tetracyclines. Steroids may be considered in selected cases, especially to reduce mass effect and improve antibiotic penetration and cerebral edema.¹¹ Surgical approaches have an important role in the management of brain abscesses. The choice of procedure depends on the operator's skills and preferences. Approaches include ultrasound, or CT-guided needle aspiration via stereotactic

procedures, bur holes, and craniotomy for localized multiple abscesses. Intravenous or intrathecal agents against certain microorganisms are considered with surgical therapy.¹²

Anesthetic management in SOL cases

Space occupying lesion (SOL) is one of the indications for surgery in the supratentorial area. Preoperative management in supratentorial surgery includes evaluating the location and size of the lesion, surgical access, patient positioning, estimated blood loss, and changes in intracranial pressure (ICP).^{10,11} Examination of the patient's neurological status including level of consciousness using the Glasgow Coma Scale (GCS), signs specific focal neurologic examination, and review of the patient for other diseases, are also performed before surgery. Anesthetic premedication in the form of benzodiazepines can be given to patients who are anxious and do not have signs of increased ICP.¹³ Other treatments being given such as corticosteroids and anticonvulsants must be continued until the time of surgery.¹⁴

The target of intraoperative management is a smooth induction, stable hemodynamics, as well as the duration and smooth emergence of anesthesia to be able to carry out an initial neurological examination.¹⁵ Induction and intubation can cause intracranial hypertension, therefore intravenous anesthesia, generally using propofol or thiopental, plus administration of intravenous lidocaine, and avoiding administration of nitric oxide can be done to prevent an increase in ICP during induction and intubation. Standard monitoring is performed on patients during induction of anesthesia. Core temperature is also monitored and a urinary catheter is inserted, especially if

hyperosmolar agents are administered at the time of surgery.¹⁶

Care should be taken to minimize Valsalva during rapid sequence induction and the emergence of general anesthesia, although blunting airway reflexes in these patients may further increase their risk of pregnancy-related aspiration. Strategies to blunt the sympathetic response to intubation include combining induction agents with opioids (eg, fentanyl 2–5 g/kg bolus or remifentanyl 1 g/kg over 1 minute) or labetalol in 5 mg increments.¹⁷

Some experts recommend replacing succinylcholine, which theoretically can cause a temporary increase in ICP due to contraction of abdominal and chest muscles, with a nondepolarizing muscle relaxant (eg, rocuronium 1.2 mg/kg) for a rapid induction sequence.^{18,19} While hyperventilation is beneficial for mothers with lowering ICP and maximizing cerebral blood flow in patients with elevated ICP, it may harm the fetus by decreasing placental blood flow.¹⁷ To balance fetal and maternal cerebral perfusion, the recommendation is to maintain maternal PaCO₂ approximately 25–30 mmHg and maternal blood pressure close to baseline.²⁰

Surgery for intracranial tumors requires several positions, such as supine, prone, lateral and sitting. An elevated patient position of approximately 30 degrees with the head straight is recommended to avoid increasing ICP by facilitating venous drainage. However, in some cases, a flexed neck position is required for surgical access even though it can cause airway obstruction and obstruction of cerebral venous return resulting in intraoperative cerebral edema.^{16,17}

CASE

The patient with the name Mrs. RW, age 32 years, female, medical record number C924583, was admitted to the hospital on April 6 2022.

The patient came without complaints, with nasal cannula oxygen therapy 3-4 liters per minute (lpm), intravenous fluid drip (IVFD) ringer lactate 20 lpm intravenous (IV), dexamethasone injection 10 mg / 12 hours IV, ranitidine injection 50 mg / 12 IV hour, vitamin B12 drip injection 1 ampoule / 12 hours IV, paracetamol 500 mg / 8 hours orally (po), folic acid 1 mg / 24 hours po, vitamin B6 10 mg / 12 hours po, isoniazid 400 mg / 24 hours , rifampin 450 mg / 24 hours, ethambutol 1000 mg / 24 hours, pyrazinamide 750 mg / 24 hours, metoclopramide injection 10 mg / 12 hours, n-acetylcysteine 200 mg / 8 hours.

The patient has no history of asthma, hypertension, diabetes mellitus, heart disease. The patient has a history of sedation or surgery on the left mammary gland, GA, post surgery is good. The patient last ate 6 hours before the procedure.

The patient has no fever or runny nose, the patient has shortness of breath. Coughing with phlegm starting from 1 month of pregnancy, shortness of breath, active fetal movements are felt. The patient experiences weakness in the right limb, the right hand can only shift. The patient can sit with assistance. The patient can sleep on his back with 2 pillows, or 45 degrees.

The general condition of the patient appeared to be moderately ill, compos mentis. The patient's vital signs include blood pressure 104/72 mmHg, pulse 102 times per minute (regular, sufficient

content and tension), respiratory rate 24-26 times per minute (regular, fast), temperature 36.4°C, SpO₂ 97% with nasal cannula 4 lpm. The patient's generalist status was within normal limits.

Hematology supporting examination (10/04/2022) showed hemoglobin 10.2g/dL post 2 PRC transfusions, hematocrit 32.5%, leukocytes 15.4 x 10³/uL, platelets 368 x 10³ /uL.

The results of the clinical chemistry examination (30/03/2022) included glucose 98, urea 11, creatinine 0.63, magnesium 0.66, calcium 2.15, sodium 131, potassium 3.5, chloride 102, quantitative CRP /HsCRP 5 .56.

Examination results (31/03/2022) TSHs 3.02 uIU/mL 0.51 – 4.94, free T4 12.85 pmol/L 10.6 – 19.4. Coagulation studies (30/3/2022) included plasma prothrombin time (PPT) prothrombin time 9.6, control PPT 11.1, partial thromboplastin time (PTTK) thromboplastin time 25.6, Control APTT 24.9, quantitative d-dimer 1740.

From the BGA examination (13/04/22 at 02.33) the patient found, pH 7.464, FiO₂ 32.0, PCO₂ 41.2, PO₂ 142.1, HCO₃ 28.9, BE (B) 4.7, SO₂c 98.9, A-aDO₂ 36.2, PFR 444. COVID-19 antigen swab examination (12/04/2022) showed negative results.

From chest x-ray examination (01/04/2022), it was found that the cast was not enlarged, opacity in the right lower middle field → DD/mass, loculated pleural effusion, infiltrate in the lower midfield of the left lung → suspect bronchopneumonia.

From the Plain Head MRI examination (31/03/2022), the results showed multiple inhomogeneous solid masses with cystic parts and intratumoral hemorrhage in the gray-white matter of the right left frontal lobe, left parietal, right parietooccipital, left cerebellum (largest size ± AP 3.6 x CC 4.6 x LL 4.6 cm on the right parietooccipital) accompanied by vasogenic edema in the right left frontal lobe, right temporal, right left parietal, right occipital, body corpus callosum, left cerebellum which presses on the right lateral ventricle and causes midline shifting to the left (± 0, 6cm)→DD/tuberculoma, abscess. There are signs of increased intracranial pressure on 3D TOF: L-ACA segment A1 appears small.

Patient assessment included G1P0A0, 32 years old, 29 weeks 3 days pregnant, 1 live fetus intrauterine, intracranial SOL suspected of multiple cerebral abscesses and tuberculoma, invasive mammary carcinoma, progressive chronic cephalgia, spastic dextral hemiparesis, bronchopneumonia, observation of improving fever.

The patient's plan is SCTP with GA ASA IIIE, postoperative ICU backup, 1 PRC blood effort from the operator, IVFD NaCL 0.9% 20 tpm, maintain O2 NC 3-4 lpm.

Intraoperative:

Table 1. Intraoperative conditions

Time	11.00	11.15	11.30	11.45	12.00	12.15	12.30
BP (mmHg)	120/86	130/90	131/92	135/110	139/119	130/90	135/111
HR (kpm)	106	105	101	102	101	106	107
RR (kpm)	14	14	14	14	14	14	14
Oxygen saturation (%)	100	100	100	100	100	100	100
Entry Medication							
Ondansetron	4 mg						
Tranexamic acid			1000 mg				
Fentanyl	50 mcg	50 mcg					
Roculax	40 mg						
Propofol	100 mg						
Vitamin K			10 mg				
Dexamethasone	10 mg						
Fluid Inlet							
RL (cc)	250		250		250		100
Fluid Out							
Urine (cc)	50		50		50		25
Bleeding (cc)			200	100			

From the results of the post-operative follow-up on H+1, the patient complained of post-operative wound pain, no shortness of breath, cough and fever. The patient's condition is good, compos mentis. Patient assessment includes P1A0 post SCTP with GA,

intracranial SOL suspected of multiple cerebral abscesses and tuberculoma, invasive mammary carcinoma, progressive chronic cephalgia, spastic right hemiparesis, bronchopneumonia, observation of improving febrile. The therapy given to the patient was IVFD

RL 20 tpm + oxytocin 20 tpm, ketorolac injection 30 mg / 8 hours IV, paracetamol 1000 mg / 8 hours PO, vitamin B/C/SF 1 tab / 12 hours PO, and vitamin A 200,000 IU / 24 PO hours.

From the results of the post-operative follow-up on H+2, the patient complained of post-operative wound pain, no shortness of breath, cough and fever. The patient's condition is good, *compos mentis*. Patient assessment includes P1A0 post SCTP with GA, intracranial SOL suspected of multiple cerebral abscesses and tuberculoma, invasive mammary carcinoma, progressive chronic cephalgia, spastic right hemiparesis, bronchopneumonia, observation of improving febrile. The therapy given to the patient was IVFD RL 20 tpm + oxytocin 20 tpm, ketorolac injection 30 mg/8 hours IV, paracetamol 1000 mg/8 hours PO, vitamin B/C/SF 1 tab/12 hours PO, and vitamin A 200,000 IU/ 24 hours PO.

DISCUSSION

Space occupying lesion (SOL) is a generalization of lesions in the intracranial space, especially those affecting the brain. In this patient there was SOL originating from multiple cerebral abscesses with a differential diagnosis of tuberculoma. This mass produces consequences in the form of increased intracranial pressure because the cranium is a space with a fixed volume. In this patient there were neurological manifestations due to SOL, namely chronic progressive cephalgia accompanied by spastic right hemiparesis. Considering the condition of the patient who was 29 weeks pregnant accompanied by the presence of SOL, termination of pregnancy was carried out. SOL in pregnant patients requires comprehensive management which includes several departments such

as nerves, obstetrics, and anesthesiologists. Comprehensive multidisciplinary management is not only in establishing the diagnosis, but also in perioperative management because it requires careful planning to balance the welfare of the mother and fetus. This requires modification of neuroanesthetic and obstetric practices that often have competing clinical goals to achieve optimal maternal and fetal safety.

Termination of pregnancy in this patient was carried out by caesarean section (CS) with general anesthesia (GA). Care should be taken to minimize Valsalva during rapid sequence induction and the emergence of general anesthesia, although blunting airway reflexes in these patients may further increase their risk of pregnancy-related aspiration. Strategies to blunt the sympathetic response to intubation include combining induction agents with opioids or labetolol. The success of the anesthesia method is determined by assessing the newborn's APGAR score. The infant may be affected directly by transplacental drug transfer or indirectly by changes in fetal-placental perfusion, or both. The risk of immediate effects from placental transfer is greatest with general anesthesia, as maternal drug exposure is greater for CS delivery.

CONCLUSION

A woman with a diagnosis of G1P0A0, 32 years old, 29 weeks 3 days pregnant, a single intrauterine live fetus with suspected intracranial SOL, multiple cerebral abscesses and tuberculoma, invasive mammary carcinoma, chronic progressive cephalgia, spastic dextral hemiparesis, bronchopneumonia and observation for improvement in febrile was consulted by the TS department obstetrics gynecology to the

anesthesiology department and intensive therapy to perform a caesarean section operation with general anesthesia (GA).

During the anesthesia and operation, there were no complications. After the operation was completed, the patient was monitored in the RR. During the monitoring period the patient's condition was good, vital signs were stable, visual analogue scale (VAS) score 0-1, no side effects were found.

These patients are considered for termination pregnancy related well-being of mother and baby. Caesarean section (SC) surgery in patients with SOL requires comprehensive multidisciplinary management not only in establishing the diagnosis, but also in perioperative management because it requires careful planning to balance the welfare of the mother and fetus.

REFERENCES

1. Butt ME, Khan SA, Chaudrhy NA, Qureshi GR. Intracranial space occupying lesions: a morphological analysis. *Biomedica*. 2005;21(Jan-Jun).
2. Kaki RR, Anuradha B, Rani BS, Rao KS, Kusumalatha P, Satyasuneetha K. IMAGING OF INTRACRANIAL SPACE OCCUPYING LESIONS- A PROSPECTIVE STUDY IN A TERTIARY CARE CENTRE- GGH, KAKINADA, A.P. *J Evid Based Med Healthc*. 2017;4(11). doi:10.18410/jebmh/2017/120
3. Satyanegara. *Ilmu Bedah Saraf*. Edisi V. Jakarta: Gramedia; 2014.
4. Sajjad A, Naroo G, Khan Z, et al. Space Occupying Lesions (SOL) of the Brain - Clinical Manifestation with Subtle Neurological Symptoms in Emergency Department. *J Adv Med Med Res*. 2018;26(3). doi:10.9734/jammr/2018/38701
5. Rughani AI. Brain Anatomy. <https://emedicine.medscape.com/article/1898830-overview#a6>. Published 2015. Accessed June 24, 2022.
6. Toh CH, Wei KC, Chang CN, et al. Differentiation of pyogenic brain abscesses from necrotic glioblastomas with use of susceptibility-weighted imaging. *Am J Neuroradiol*. 2012;33(8). doi:10.3174/ajnr.A2986
7. Toh CH, Wei KC, Ng SH, Wan YL, Lin CP, Castillo M. Differentiation of brain abscesses from necrotic glioblastomas and cystic metastatic brain tumors with diffusion tensor imaging. *Am J Neuroradiol*. 2011;32(9). doi:10.3174/ajnr.A2581
8. Moon S-J, Ginat DT, Tubbs RS, Moisi MD. Tumor of The Brain. *Cent Nerv Syst Cancer Rehabil*. 2019:27-34.
9. Bokhari MR, Mesfin. FB. Brain Abscess. In: *StatPearls* [Internet]. Treasure Island (FL): StatPearls Publishing; 2022.
10. Burnstein R, Banerjee A. Anesthesia for Supratentorial Surgery. *Essentials Neuroanesthesia Neurointensive Care*. 2008:106-110. doi:10.1016/B978-141604653-0.10016-0
11. Rao GSU. Anaesthetic Management of Supratentorial Intracranial Tumours Brain. 2005;2(October):1-9.
12. Gruenbaum SE, Meng L, Bilotta F. Recent trends in the anesthetic management of craniotomy for supratentorial tumor resection. *Curr Opin Anaesthesiol*. 2016;29(5):552-557. doi:10.1097/ACO.0000000000000365

13. Leffert, L.R., Schwamm, L.H., 2013. Neuraxial anesthesia in parturients with intracranial pathology: A comprehensive review and reassessment of risk. *Anesthesiology*. doi:10.1097/ALN.0b013e31829374c2
14. Kumala Fajar Apsari, R., Suryono, B., Shinta, S., 2020. Manajemen anestesi pada pasien Seksio Sesarea Primigravida dengan Glioblastoma Multiforme. *Jurnal Anestesi Obstetri Indonesia* 2, 35–43. doi:10.47507/obstetri.v2i1.3
15. Bleaser T, Van Der Veeken L, Fieuws S, et al. Effects of general anaesthesia during pregnancy on neurocognitive development of the fetus: a systematic review and meta-analysis. *Br J Anaesth*. 2021;126(6):1128-1140
16. Marulasiddappa V, Raghavendra B, Nethra H. Anaesthetic management of a pregnant patient with intracranial space occupying lesion for craniotomy. *Indian J Anaesth*. 2014;58(6):739-741
17. Ramachandran A, Segaran S, Nikithamani, Ranjan R V. Neuraxial anaesthesia in a parturient with space occupying lesion in brain for caesarean section: Demystifying the myth – A case report with review. *J Obstet Anaesth Crit Care* 2022;12:164-6
18. Durrani S, Akbar S, Heena H. Breast Cancer During Pregnancy. *Cureus*. 2018;10(7):e2941.
19. Hayashi, T.; Katayama, M.; Miyasaka, K.. General anesthesia for breast cancer surgery during pregnancy: a retrospective review at a breast cancer center in Tokyo between 1999 - 2011: 11AP5-2. *European Journal of Anaesthesiology* 30():p 178-178, June 2013.
20. Brito V, Niederman MS. Pneumonia complicating pregnancy. *Clin Chest Med*. 2011;32(1):121-132.