

Double Whammy Cases of Severe Mitral Stenosis in Peripartum: A Survival Case Series

Lourensia Brigita Astern Praha^{✉*}, Rizqon Rohmatussadeli*, M. Fauzilar Ahnaf*, Besari Adi Pramono**, Rahmad Rizal Wicaksono**, R. Soerjo Hadijono**

*Department of Cardiology and Vascular, Faculty of Medicine, Universitas Diponegoro/Dr. Kariadi General Hospital, Semarang, Indonesia

**Department of Obstetrics-gynecology, Faculty of Medicine, Universitas Diponegoro/Dr. Kariadi General Hospital, Semarang, Indonesia

✉Correspondence: lourensiabrigita@yahoo.com

ABSTRACT

Background: Valvular heart disease in pregnancy is still not widely studied. The combination of mitral stenosis and the physiology of pregnancy for both mother and fetus often result in poor hemodynamics, and management during labor and peripartum period greatly determines the prognosis of both lives.

Case: A 42 years old G3P2A0 (Case A) and A 33 years old G3P1A1 (Case B) both had a history of previous SC labor, presented worsening shortness of breath since 2nd trimester, coughing and swelling in both legs, also unable to rest in a flat position. especially, case B was frequent re-hospitalized with prolonged LOS during 2nd – the 3rd trimester due to acute lung edema. We found a mid-diastolic murmur grade II/IV at the apex. Electrocardiography (ECG) of case A: sinus rhythm, left atrial enlargement (LAE), while case B: AF rapid response. The echocardiography of case A revealed severe MS, while case B revealed severe MS, moderate tricuspid regurgitation and, a high probability for PH. Those findings support the diagnosis of severe mitral stenosis and rheumatic heart disease in pregnancy, then they were programmed to do balloon mitral valvuloplasty (BMV) in 3rd trimester.

Discussion: The BMV was performed, and succeeded in case A reducing the mitral valve pressure gradient (MV PG) from 24.7mmHg to 12.1mmHg by using local anesthesia along the procedure, while in case B specifically done BMV with general anesthesia due to supraventricular tachycardia (SVT) and pulmonal congestive during procedure, reducing the MV PG from 17.7mmHg to 8.6mmHg, as well as improvement in symptoms, up to pregnancy was terminated as obstetric indication by SC on 36-37 weeks' gestation in both cases. The baby born was healthy with weights of each case 2340gr and 2630gr.

Conclusion: Mitral stenosis in the peripartum needs to be managed by interprofessional collaboration properly, to decrease the risk of morbidity and mortality for the mother and fetus.

Keywords: anesthesia agent; balloon mitral valvuloplasty; mitral stenosis; peripartum; pregnancy

INTRODUCTION

The diagnosis of mitral stenosis (MS) is considered clinically significant if the valve area is $\leq 1.5 \text{ cm}^2$. This narrowing impedes the normal blood flow from the left atrium to the left ventricle, leading to a range of symptoms and potential complications. While MS can occur at any stage of life, peripartum MS specifically refers to the development or exacerbation of the condition during the period surrounding childbirth. The reference measurement of MS severity is planimetry. Doppler-pressure half-time is less reliable but can be used during pregnancy. Based on the Registry of Pregnancy and Cardiac Disease (ROPAC), the prevalence of MS during pregnancy showed 70% in mild MS, 39.2% in moderate MS, and 19.8% in severe MS. The mortality itself is higher in low-middle-income countries like Indonesia.^{1,2}

In women with pre-existing MS, pregnancy-related physiological alterations can worsen the narrowing of the mitral valve and result in peripartum complications. Peripartum MS poses unique challenges to both the mother and the unborn child. The compromised blood flow through the narrowed valve can lead to symptoms such as shortness of breath, fatigue, palpitations, and edema. In severe cases, it may lead to heart failure or other serious cardiac events, potentially affecting both the mother and the baby's well-being. The complications which can be found in the fetuses; are 20-30% prematurely born, 5-20% intrauterine growth restriction (IUGR), and fetal death found 1-5%. In this context, awareness of the condition's potential risks, early detection, and timely intervention are critical in ensuring the best possible outcomes for both the mother and the baby.

CASE

We presented both pregnancy mothers were referred to the cardiovascular department. who had severe MS and developed worsening complaints in third trimester of pregnancy. All patients underwent balloon mitral valvuloplasty (BMV) before labor. These were performed in Dr. Kariadi General Hospital, Semarang, Indonesia.

Case A

Named Mrs. SS, 42 years old Gravida 3 Para 2 Abortus 0. At 22 weeks of gestation, the patient complained of shortness of breath, and getting tired easily. The history of two previous pregnancy labors by caesarean section (SC) due to obstructed labors. The physical examination; she was in good hemodynamic, her body mass index (BMI) was overweight based on World Health Organization (WHO) criteria, diminished S1, normal S2, mid-diastolic murmur (MDM) grade II/IV punctum maximum (PM) at the apex was found, and edema in lower extremities. Transthoracic echocardiography examination pre-BMV revealed left atrial dilated by 54 mm and severe MS by the quantification mitral valve area planimetry 0.7 cm^2 , mean pressure gradient 24 mmHg, Wilkin's score 7. She was performed BMV procedure at 35 weeks of gestation.

Case B

Named Mrs. DR, 33 years old Gravida 3 Para 1 Abortus 1. The patient complained of shortness of breath in the past 21 weeks of gestation. Previously at 8 weeks gestation, she already started shortness of breath. The patient was frequently re-hospitalized due to acute lung oedema. The history of first pregnancy was terminated by SC due to preeclampsia.

The physical examination; she was tachypnoea 26 times/minute and oxygen saturation was 94% on the nasal cannule, BMI was obese grade III by WHO criteria, S1 S2 irregularly irregular, pansystolic murmur grade III/VI left lower sternal border, MDM gr II/IV PM at the apex, rales 1/3 in both lungs, edema lower extremities. Transthoracic echocardiography examination pre-BMV revealed left atrial dilated by 48 mm and severe MS by the quantification mitral valve area planimetry 1.0 cm², mean pressure gradient 18 mmHg Wilkin's score 5 and moderate tricuspid regurgitation by the quantification Vmax 4.2 m/s maximum pressure gradient 72 mmHg with conclusion of high probability for pulmonary hypertension. Then she was performed BMV at 31 weeks gestation.

The procedures were performed BMV with femoral approach, and Case A under local anesthesia (lidocaine injection agent 2% 10 ml) to do

procedure BMV, within specialty in Case B due to frequent SVT and pulmonal congestive during procedure, then under general anesthesia using fentanyl Inj. 1-2 mcg/kgbw, then adding the muscle relaxant agent rocuronium 0.6-1.2 mg/kgbw followed by rapid sequencing intubation and to maintenance hemodynamics by sevoflurane 1 MAC (2%) MAP targeted 70mmHg. The BMV was succeeded in both cases; by reducing the mitral valve pressure gradient from 24.7mmHg to 12.1mmHg (Case A) and reducing the mitral valve pressure gradient from 17.7mmHg to 8.6mmHg (Case B).

The evaluation of transthoracic echocardiography post-procedural of BMV with quantification for mitral valve area by planimetry 1.9cm² and mean pressure gradient 10mmHg (Case A), whereas the quantification mitral valve area by planimetry 1.77cm² and mean pressure gradient 9mmHg (Case B).

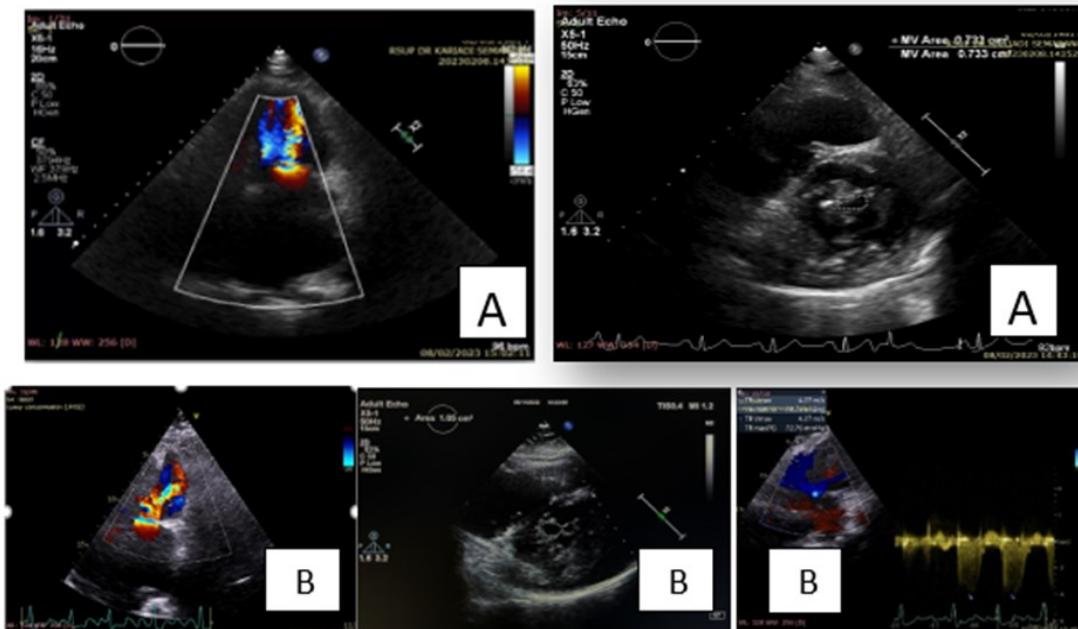


Figure 1. Case A revealed severe mitral stenosis, while Case B revealed several mitral stenosis with moderate Tricuspid regurgitation and high probability for pulmonary hypertension (Pre-Procedural of BMV)

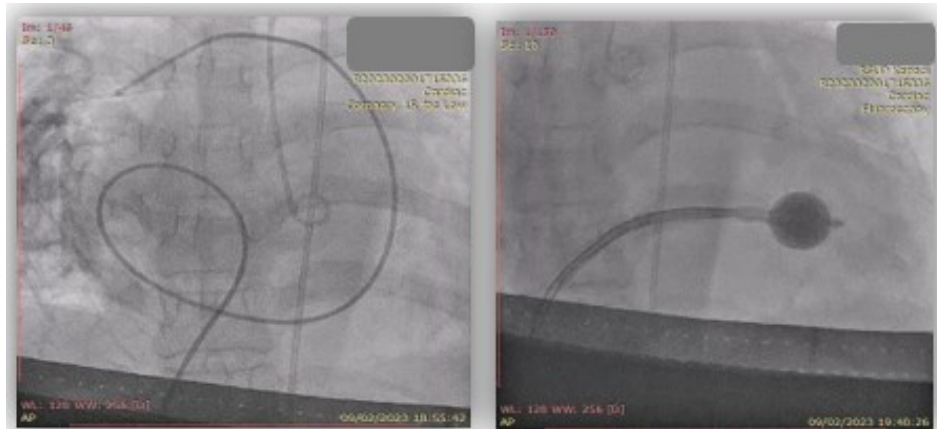


Figure 2. The BMV were succeeded in both cases, by reducing the mitral valve pressure gradient from 24.7 mmHg to 12.1 mmHg (Case A) and reduced the mitral valve pressure gradient from 17.7 mmHg to 8.6 mmHg (Case B)

DISCUSSION

Hemodynamic Changes During Pregnancy and Childbirth

Physiological changes in pregnancy begin to occur in the first trimester, but these changes will continue into the second and third trimesters. These physiological changes include increased blood volume, cardiac output, stroke volume, heart rate, and decreased blood pressure and peripheral vascular resistance. Cardiac output increases by 40% starting in the 5th week of gestation and reaches a peak at 32 weeks. These physiological changes will reach their peak between the second and third trimesters which can cause symptoms if the pregnant woman has heart disease. These physiological changes will disappear within 3-6 months after delivery.^{3,4,5}

During labor, the mother's hemodynamics are affected by several factors, including pain, method of delivery, and analgesia. Cardiac output increases to 30% in the 1st stage and up to 80% immediately after labor. The increase in cardiac output caused by an increase in stroke volume will continue until 24 hours after labor. Where each uterine contraction, 300-500 mL of

blood is auto-transfused from the placenta into the maternal circulation. In addition, systolic and diastolic blood pressure increases with each uterine contraction. Maternal hemodynamic changes dramatically in the first 24 hours postpartum. Preload increases after loss of inferior vena cava pressure due to uterine compression. This causes in the postpartum period, women with heart disease will experience the risk of symptoms of heart failure. In addition, pregnancy is hypercoagulable, thus making women more prone to thrombosis. The risk of thrombosis is highest within 6 weeks after delivery, and the increased risk occurs up to 12 weeks after delivery.^{6,7}

Mitral stenosis in Peripartum

In general, patients with moderate to severe mitral stenosis tolerate pregnancy poorly. Increased plasma volume and heart rate will worsen the patient's condition so the NYHA functional class in pregnant women will increase by at least 1 point. Patients who are initially asymptomatic may become NYHA II, and patients who are initially NYHA II may become NYHA III. Mitral stenosis in women often becomes symptomatic during pregnancy when cardiac output increases to 70%. Referring to the Gorlin

formula, an increase in cardiac output of 1.7 times will increase the transvalvular gradient by 2.89 times. So if the pre-pregnancy gradient of 4mmHg can become 11mmHg during the second trimester of pregnancy, this will cause symptoms. The highest risk of mortality for mothers during childbirth and immediately after delivery. The sudden increase in preload after delivery, due to autotransfusion from the uterus, can overwhelm the maternal circulation and cause severe pulmonary edema. This autotransfusion lasts for approximately 24-72 hours after delivery.⁸

Risk stratification is especially important in pregnant women with heart disease. Where the Zahara risk score is used for pregnant women with congenital heart disease, while for pregnant women with heart valve disease and artificial heart valves using the Carpreg score. World Health Organization (WHO) classifies pregnant women with congenital and acquired heart disease into 4 classes, from low to high risk. Patients with WHO class 4 are at greatest risk, in whom pregnancy is contraindicated because of the high mortality rate.⁹

Intervention

Counseling for pregnant women regarding percutaneous intervention therapy needs special attention and approach. During pregnancy, percutaneous intervention on the mitral valve is recommended after entering 20 weeks' gestation with consideration for pregnant women with NYHA class III/IV and/or estimated systolic *pulmonary artery pressure* (PAP) \geq 50 mmHg, who have received optimal treatment without any contraindications. Percutaneous intervention is recommended after entering 4 months of gestation in the second trimester. By this time, organogenesis is completed, the

fetal thyroid is inactive, and the volume of the uterus is still small, so that there is a greater distance between the fetus and the chest wall than in the following months. Close monitoring is required within a few days postpartum. The prognosis will depend on the risk of developing stenosis and restenosis progression after intervention, so regular follow-up is necessary.⁹

Anesthetic Agents in the Peripartum

Maintaining hemodynamics after induction of anesthesia is a challenge. Anesthetic management of patients with heart failure especially in peripartum whether general or regional anesthesia is appropriate remains unclear.⁹ Therefore, only general anesthesia is indicated for patients with severe cardiac and respiratory failure.^{10,11} We considered these in Case B where the patient suffered severe mitral stenosis and had a high probability of Pulmonary Hypertension by transthoracic echocardiography.¹² Any anesthetic agent can lead to a decrease in afterload, potentially resulting in hemodynamic collapse. Therefore, midazolam and fentanyl are commonly preferred in patients with cardiac dysfunction because of the relatively slow onset of the anesthetic effect and low effect on hemodynamics, respectively.¹³

Here are some pros and cons of using general anesthesia in pregnancy. The pros of using general anesthesia in pregnancy include ensuring control and stability (the patient remains completely unaware and immobile during the procedure), effective pain management, and maintain stable maternal vital signs during the procedure. Meanwhile, the cons are potential risks to the developing fetus (especially at first trimester), could trigger preterm labor, and the risk of uterine atony.

Table 1. Summary of case series can be described below this

Case A	Case B
42 years old	33 years old
G3P2A0	G3P1A1
Symptom was arisen since 22 weeks' gestation	Symptom was arisen since 24 weeks' gestation
History of SC 2 times due to obstructed labor	History of SC 1 time due to Severe Preeclampsia and Abortus
Overweight	Obese
ECG: Sinus rhythm, normoaxis, qrs rate 85 bpm, LAE	ECG: Atrial fibrillation, normoaxis, qrs rate 114 bpm
BMV done in 35 weeks' gestation	BMV done in 32 weeks' gestation
Echo pre BMV: Severe MS (+) with MVA 0.4 cm ² , mean PG 24 mmHg, PH (-)	Echo pre BMV: Severe MS (+) with MVA 1.0cm ² , mean PG 21 mmHg, Moderate TR, High probability for PH
BMV: reducing the mitral pressure gradient from 24.7 mmHg to 12.1 mmHg	BMV: reducing the mitral pressure gradient from 17.7 mmHg to 8.6 mmHg
Echo post BMV: MS Moderate, mva by planimetry 1.12 cm ² , mean PG 10 mmHg, PH (-)	Echo post BMV: MS moderate (MVA by plannimetry 1.7 cm ² , mean PG 9 mmHg
Labor of ♀ baby born, 2340 gr, healthy	Labor of ♂ baby born, 2630 gr, healthy

It has been illustrated in both cases a 42-year-old and 33 years old woman were found with the chief complaint of shortness of breath. Shortness of breath has been getting worse since the last 3-4 months ago, previously mild shortness of breath could be reduced with rest. This indicates the progressive course of the disease. Dyspnea on exertion accompanied by decreased activity tolerance, and edema in both legs, are symptoms consistent with heart failure with mitral stenosis. Based on the data of history and physical examination, the patients were diagnosed with functional class III and IV chronic heart failure due to valvular heart disease. This valvular heart disease has probably been around for a long time, this can be seen from the enlargement of the left heart. Narrowing of mitral valve and increased HR of pregnancy limits LV filling resulting in decreased stroke volume and cardiac output. As a result, the heart cannot cope with situations warranting increased metabolic demand or increased blood volume. Patients with these conditions are at high risk during the peripartum.

The consideration to choose general anesthesia in case B is based on its complexity. Basic goals for anesthetic management of MS patients are to avoid tachycardia; revert acute AF to sinus rhythm; avoid aortocaval compression; maintain adequate venous return and systemic vascular resistance (SVR); and prevent increased pulmonary vascular resistance. The Case B, needs to be aware of atrial fibrillation which may result in hemodynamic deterioration and decreased cardiac output in these patients with poor cardiac reserve and hence requires faster intervention and cautious use of medication to avoid harm to the fetus and to prevent thromboembolism. During BMV procedure, the patient experienced frequent SVT and pulmonal congestive. Due to its complexity, emergency, duration, and high degree of immobility of procedure BMV, general anesthesia using fentanyl was chosen in case B to avoid further complications during procedure. The advantages of using fentanyl is increasing pulmonary artery pressure, increasing the RV overload (by

TAPSE 21mm), which benefits to LV unloading, and decreasing congestion with optimize diffusion. While monitoring fetal bradycardia was not found. There are no controlled studies examining the best type of anesthesia in these patients and guidelines are lacking. It's crucial to thoroughly assess the risk-benefit ratio and consider alternatives that minimize risks to both mother and fetus, education and information is really needed to patient and family. Selection of anesthesia technique, intensive hemodynamic monitoring, and slow and cautious titration of oxytocic drugs are important in decreasing the perioperative fetomaternal morbidity and mortality.^{14,15}

Before and after BMV, a mitral valve gradient was examined by tapping the right heart, with the results of BMV reducing the mitral valve gradient and transthoracic echocardiography post-BMV was also performed and the planimetric mitral valve area increased from before BMV. Clinically the patient was improving, the pregnancy could be maintained as optimally as possible until the baby's weight was considered to be born. At 36 and 37 weeks of gestation, both patients were hospitalized for a caesarean section procedure without any complications for the mother and baby born.

CONCLUSION

Mitral stenosis in the peripartum needs to be managed by interprofessional collaboration properly, to decrease the risk of morbidity and mortality for the mother and fetus.

REFERENCES

1. Youssef G. Mitral stenosis in pregnant patients escardio.org/Journals/E-Journal-of-Cardiology-Practice. 2018 Jul 25;16
2. Van Hagen IM, Thorne SA, Taha N, Youssef G, Elnagar A, Gabriel H, El Rakshy Y, Iung B, Johnson MR, Hall R, Roos-Hesselink JW; ROPAC Investigators and EORP Team. Pregnancy Outcomes in Women With Rheumatic Mitral Valve Disease: Results From the Registry of Pregnancy and Cardiac Disease. *Circulation*. 2018;137:806-16. DOI: <https://doi.org/10.1161/circulationaha.117.032561>
3. Yıldırım E, Çelik M, Akpak YK. Mitral Stenosis and Pregnancy. *Open Sci J Clin Med*. 2015 Nov 11;3:220-3
4. Kannan M, Vijayanand G. Mitral stenosis and pregnancy: Current concepts in anaesthetic practice. *Indian J Anaesth*. 2010 Sep 1;54:439-44. DOI: <https://doi.org/10.4103/0019-5049.71043>
5. Soma-pillay P, Nelson-piercy C, Tolppanen H, Mebazaa A. Physiological changes in pregnancy. *Cardiovasc J Afr*. 2016;27(2):89-94. DOI: <https://doi.org/10.5830/cvja-2016-021>
6. Lindley, K; Williams D. Valvular Heart Disease in Pregnancy. *JACC*. 2018;1-15
7. Nanna M, Stergiopoulos K. Pregnancy complicated by valvular heart disease: an update. *J Am Heart Assoc* 2014;3:e000712. DOI: <https://doi.org/10.1161/jaha.113.000712>

8. Carabello BA. Mitral Stenosis. In: Fuster, V; Walsh, Richard A; Harrington RA, editor. *Hurst's the Heart*. 13th ed. New York: McGraw Hill; 2011. p. 1738–42.e
9. Vera Regitz-Zagrosek et al. ESC Guidelines for the management of cardiovascular diseases during pregnancy: The Task Force for the Management of Cardiovascular Diseases during Pregnancy of the European Society of Cardiology (ESC). *European Heart Journal*. Volume 39:Issue 34. 07 September 2018;Pages 3165–3241. Available from: <https://doi.org/10.1093/eurheartj/ehy340>
10. Ituk US, Habib AS, Polin CM, et al. Anesthetic management and outcomes of parturients with dilated cardiomyopathy in an academic centre. *Can J Anaesth* 2015; 62: 278–288. DOI: 10.1007/s12630-014-0290-y
11. Chestnut DH. 4th ed. Philadelphia: Mosby Elsevier. *Obstetric anesthesia: Principles and practice*; 2009
12. Alagandala A, Vaswani D, et al. Maternal Outcome in Mitral Valve Disease with Pulmonary Hypertension: Two Case Reports. *Indian J Cardiovasc Dis Women-WINCARS* 2018;3:204–208. DOI: <https://doi.org/10.1055/s-0038-1676912>
13. Kawamoto Y, Nishihara T, Aono J, Nandate H, Hamada T, Yasuoka T, et al. Perioperative management of emergent cesarean section in a patient with peripartum cardiomyopathy and orthopnea: a case report. *J Int Med Res*; 49. Epub ahead of print 2021. DOI: 10.1177/03000605211063077
14. Martins LC, Freire CM, Capuruçu CA, Nunes MdoC, Rezende CA. Risk prediction of cardiovascular complications in pregnant women with heart disease. *Arq Bras Cardiol* 2016;106(4):289–296. DOI: <https://doi.org/10.5935/abc.20160028>
15. Hemlata PG, Tewari S, Chatterjee A. Anaesthetic considerations for balloon mitral valvuloplasty in pregnant patient with severe mitral stenosis: a case report and review of literature. *J Clin Diagn Res* 2017;11(9):UD01–UD03. DOI: <https://doi.org/10.7860/jcdr/2017/28379.10579>