

## ICU Management of Post-Craniotomy Patients with Schwannoma Vestibular Tumor Removal

Andhika Marthsyal Pratama✉\*, Untung Widodo\*\*

\*Faculty of Medicine, Public Health and Nursing, Gadjah Mada University/RSUP Dr. Sardjito, Yogyakarta, Indonesia

\*\*Department of Anesthesiology and Intensive Therapy, Faculty of Medicine, Public Health and Nursing, Gadjah Mada University/RSUP Dr. Sardjito, Yogyakarta, Indonesia

✉Correspondence: [andhika.mp@gmail.com](mailto:andhika.mp@gmail.com)

### ABSTRACT

**Background:** Vestibular schwannoma (VS) is a relatively common tumor that arises from the vestibulocochlear nerve (CN VIII) and represents 80% of cerebellopontine angle (CPA) masses. CPA tumors are mostly benign, slow growing with low malignant potential (~1%). VS have rarely been reported, and there is a lack of in-depth discussion on the experience of management of massive acoustic neuromas in ICU. It represents the case in which the patient presented with obstructive hydrocephalus and progressive neurological deficits. The purpose of this case report is to understand the management of post-operative patients with VS with several comorbidities in the ICU.

**Case:** We present a 53 years old woman with a giant VS and obstructive hydrocephalus. An imaging findings revealed a brain tumor in the CPA region and obstructive hydrocephalus. Consequently, she relieved her hydrocephalus with a ventriculoperitoneal shunt (VP shunt). After 1.5 years, her mental condition deteriorated, and her left limb muscle strength gradually decreased. Under a joint consultation with Department of Neurosurgery and Anesthesiology, she underwent tumor removal. Upon discharge, the previously observed neurological deficits, which were reversible had been successfully resolved. The neuroimaging confirmed the complete tumor removal, while the neuropathologic examination revealed a VS.

**Discussion:** If untreated, an acoustic neuroma can grow large enough to cause pressure on the brain stem. The tumor can block the flow of cerebrospinal fluid (CSF) between the brain and the spinal cord, causing a buildup of the fluid in the brain. Because the skull is a closed structure, excess fluid in the brain (hydrocephalus) can press against the brain, causing unsteady movement and lack of coordination (ataxia), headaches and confusion. Patients with brainstem compression had significantly longer mean LOS than patients without. Also, the dissection of the facial nerve from the tumor in order to preserve it can sometimes cause swelling, which can result in weakness or paralysis (complete or partial loss of muscle function). This is usually temporary but can take weeks to months to recover. After the operation, the patient was treated in the ICU, a ventilator was installed, insulin was given to regulate blood sugar and anti-hypertension medication for maintaining blood pressure. During treatment in the ICU, adequate fluids and nutrition are provided. Monitoring is carried out on cardiovascular function, hemodynamics and

respiration by monitoring blood pressure, electrocardiogram (ECG), oxygen saturation. The patient was moved to high care unit (HCU) after being treated for 3 days in the ICU. **Conclusion:** Postoperative therapy is more focused on supportive therapy, including maintaining the airway, regulating blood sugar, blood pressure and providing mechanical ventilation to maintain adequate oxygenation.

**Keywords:** acoustic neuroma; brainstem compression; cerebellopontine angle; diabetes mellitus type 2; hydrocephalus; vestibular schwannoma

## INTRODUCTION

Acoustic neuroma, also known as vestibular schwannoma (VS), is a non-cancerous tumor that occurs in the ear, and can affect hearing and balance. VS is a slow-growing brain tumor that develops in the vestibulocochlear nerve. This tumor is non-cancerous and benign, formed due to the abnormal growth of Schwann cells. When tumors develop in the hearing and balance nerves, the main symptoms are hearing loss, ringing in the ears, and loss of balance. Larger tumors can make pressure on adjacent cranial nerves and the surrounding brain causing hydrocephalus, numbness or pain in the face and difficulty of swallowing or speaking. If left untreated, compression of the brainstem can be fatal.<sup>1</sup>

This tumor is caused by the damage to the genetic material in the nerve layer which functions for balance. The cause of this genetic damage is unknown. It is not caused by any action that has been taken and is not obtained from other people. This is also not a hereditary disease. This condition is slightly different to a rare condition called Neurofibromatosis type 2 (NF2), in which a person may have multiple benign lesions. Only a 5% incidence of VS in people has NF2, and this condition usually appears in teenagers or young adults.

About 40% of VS grow after diagnosis, however the growth rate is usually very slow, averaging 1-2mm per year. Sometimes it can grow faster and the growth pattern varies greatly.<sup>2</sup>

VS also known as acoustic neuroma, is a relatively common tumor that arises from the vestibulocochlear nerve (CN VIII) and represents ~80% of CPA masses. The CPA is a triangular space in the posterior cranial fossa bounded by the tentorium superiorly, the brainstem posteromedially and the petrous part of the temporal bone posterolaterally. It is a major landmark anatomically and clinically because it is occupied by the CPA, which houses cranial nerves V, VI, VII, and VIII along with the anterior inferior cerebellar artery.<sup>3</sup>

CPA tumors are mostly benign, slow-growing tumors with low malignant potential (~1%). The etiology of VS remains unknown. However, there are two main types, Sporadic: These are unilateral tumors and most commonly appear between the fourth and sixth decades of life, and the other is associated with NF2: the most common presentation is bilateral acoustic neuroma in younger patients with a positive family history. NF2 results from a mutation on chromosome 22q12. This mutation causes an increased risk of other intracranial tumors as well.<sup>3</sup>

**CASE**

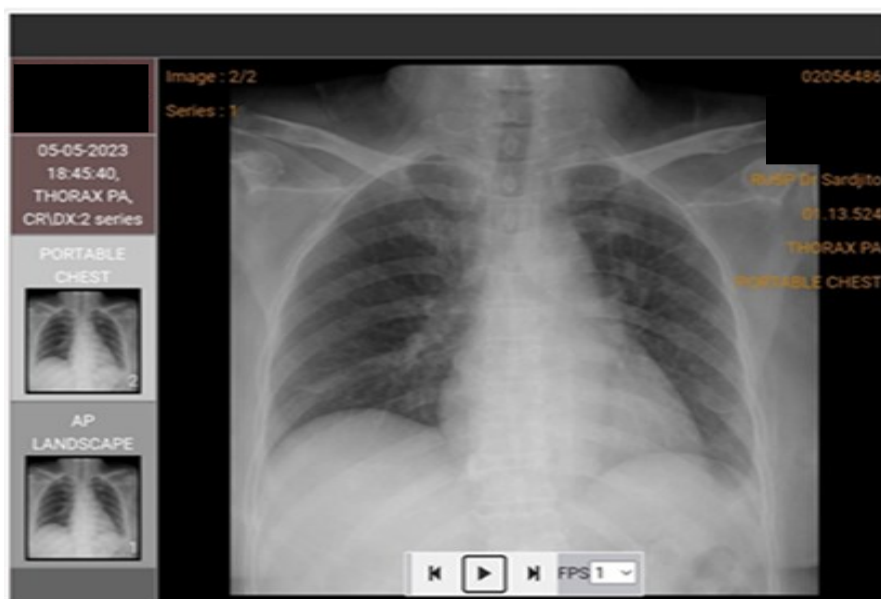
A 53 years old female patient came to the emergency room with complaints of often slurring her words and forgetting easily since 3 weeks before come to the hospital. Complaints accompanied by weakness in the left side of the body which is getting worse.

1.5 years ago, patient often complained of severe headaches all over the head with severe intensity accompanied by weakness in the left limbs. 1 year before entering the hospital, complaints of persistent headaches and weakness in the left side of the body also persisted. The patient was then taken to PKU Muhammadiyah Solo Hospital for a brain contrast MRI and it was said that there was a brain tumor accompanied by hydrocephalus. A VP shunt was installed and patient was treated for 1 week. The patient also has a history of type 2 diabetes mellitus for 5 years, and currently controlled with 2 x 20 units of Novorapid. When the patient come back for controlling her disease at PKU Muhammadiyah Solo Hospital, an MRI

was done and it was said that the CPA tumor was getting bigger, then the patient was referred to Dr. Sardjito Hospital, was examined and hospitalized on May 5 2023.

The patient was consulted to a neurosurgery specialist for surgery to remove the tumor. 5 days before come to the the hospital the patient was checked at the neurology clinic. Extremity movements still appear slow, the body becomes increasingly weak. Talking less, can not interacting properly and forgetting more easily. Eating and drinking is decreasing. Defecation requires a laxative. Urine output become lesser.

On the day of admission patient appeared increasingly weak and sleepy. Eating and drinking lesser. After the patient received in the emergency room and undergoes an initial examination, then she is treated in the ward. The patient is prepared to undergo surgery to remove the CPA tumor on May 26 2023.

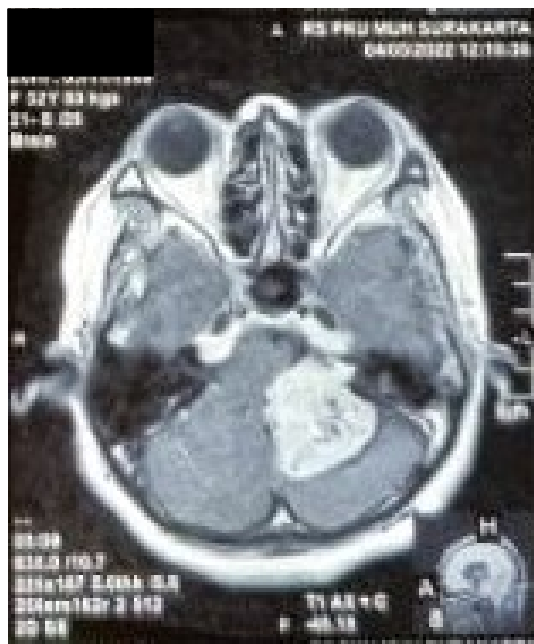


**Figure 1.** Preoperative Chest X-Ray

Physical examination revealed that her general condition appeared weak, her consciousness apathetic. Airway examination is clear without breathing aids. Spontaneous breathing, with respiratory rate 20 x/min, rhonchi -/-, wheezing -/-, vesicular +/+. Hemodynamic examination, blood pressure 139/87 mmHg, heart rate 98 x/min, pure S1-2. Neurological status E3M5V4, pupil isocore 3mm/3mm, light

reflex +/+, temperature 37.2° C. Body weight / height: 70 kg/160 cm.

Laboratory examination results showed: Hb 12.7, Leukocytes 6.6, Erythrocytes 4.22, Hematocrit 39.3, Platelets 258,000, PPT 9.5, APTT 24.3, INR 0.87, DDimer 353, fibrin 423, albumin 3.70, SGOT 18, SGPT 24, ureum 11, creatinine 0.50, blood sugar 86, sodium 137, potassium 4.1, chloride 102, calcium 2.09, magnesium 2.3.



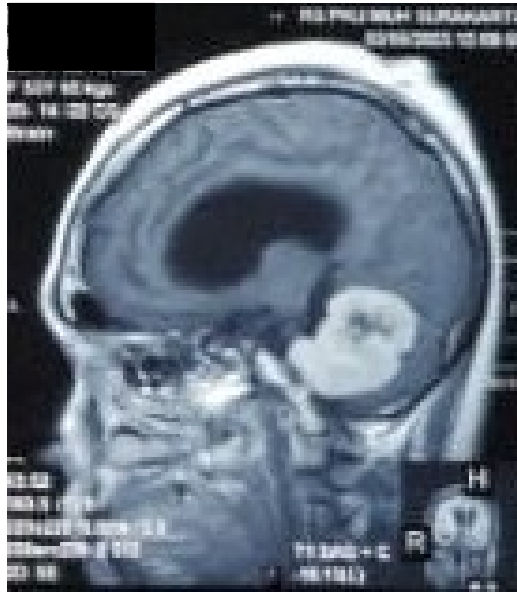**Figure 2.** Preoperative MRI

Chest x-ray examination showed that the cor and pulmo were within normal limits. MRI examination showed that the meningioma in the left CPA was narrowing to the IV ventricle, dilatation of the III ventricle and bilateral lateralis (hydrocephalus obstructivus at the level of the aqueductus silvii), bilateral ethmoidal and sphenoidal rhinosinusitis, compared to the old MRI the size of the tumor was enlarged.

The patient was assessed with a diagnosis: Postoperative craniotomy removal tumor ec vestibular

schwannoma (VS), left hemiparesis cum LN VIII left ec CPA tumor, hydrocephalus on VP shunt, diabetes mellitus type 2.

The patient was admitted to the ICU on May 26 2023 at 14.00 WIB from the operating room accompanied by the anesthesia team in a sedated state with ETT No. 7.0 on Bagging with O2 10 lpm installed, IV line installed in the right hand, triple lumen CVC in the right subclavia and artery line on the right radial artery.



**Figure 3.** Preoperative MRI

The patient was given mechanical ventilation with PSIMV, PC 10, RR 15, PS 10, PEEP 5, FiO<sub>2</sub> 50%, SpO<sub>2</sub> 98%. Fluid therapy with NaCl 0.9% 30 cc/kg, ceftriaxone 2x1 gr iv, mannitol 2x125 cc iv, phenytoin 3x100 mg iv, dexamethasone 4x5 mg iv, omeprazole 3x40 mg iv, paracetamol 3x1000 mg iv, tranexamic acid 3x1000 mg iv, fentanyl titration on syringe pump, midazolam titration on syringe pump. The patient is weaned from the ventilator gradually. On May 28 2023, adequate oxygenation results were obtained, indicated by blood gas analysis results of pH 7.403, pCO<sub>2</sub> 33.6, pO<sub>2</sub> 135.1, HCO<sub>3</sub> 20.04, SO<sub>2</sub> 99, with an oxygen fraction of 40%, the patient was then extubated on May 29 2023 continued with oxygenation using a non-rebreathing mask (NRM) 10 lpm. A blood gas analysis examination of the patient after extubation showed a PaO<sub>2</sub>/FiO<sub>2</sub> ratio (PFR) of 365 with an oxygen fraction of 50%. Oxygenation was reduced using a 3 lpm nasal cannula, blood gas analysis results showed PFR 279 with an oxygen fraction of 30%.

On May 30 2023, the patient's condition improved, with a respiratory rate of 20 x/minute with oxygen saturation of 99% using a 3 lpm O<sub>2</sub> nasal cannula. From the laboratory examination, the results of the blood gas analysis showed that PFR was 402, and post-ICU evaluation chest x-ray examination showed that patient cor and pulmo were within normal limits. Patient nutritional support during treatment is also considered to fulfill the patient's calories. With the patient's condition improving, the patient was transferred to HCU with a regular suction program and chest physiotherapy to speed up recovery.

### DISCUSSION

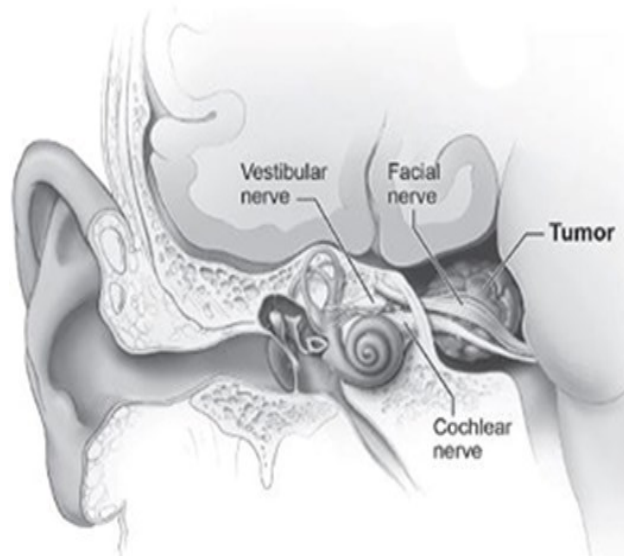
Reported management of patient in the ICU of a 53 years old woman. Patient came from the operating room after craniotomy removal of the CPA tumor.

VS originates from Schwann cells which produce the myelin sheath and arises from the superior and inferior vestibular segments of cranial nerve VIII. The incidence of VS is estimated at 1.2 per 100,000 people per year, and is expected

to increase, partly due to incidental diagnosis. VS accounts for 8%–10% of intracranial primary tumors and 70–85% of CPA tumors. Less than 10% of VS complications result in severe bleeding.<sup>4</sup> Although VS is the most frequently encountered tumor in the CPA area, clinically significant Intra Tumoral Hematoma (ITH) is rare. Patients with VS usually have symptoms of gradually progressive hearing loss such as unilateral high-frequency sensorineural hearing loss and tinnitus. Paralysis of the trigeminal nerve and facial nerve is relatively rare in 9% and 6% of patients, respectively. In contrast, for hemorrhagic VS, more than a quarter of patients reported trigeminal nerve palsy and 47%

had facial nerve palsy. Rapid tumor expansion secondary to ITH can result in acute stretching of already tenuous vestibulocochlear, facial, or trigeminal nerves resulting in a higher incidence of deficits at presentation.<sup>5</sup>

The pathophysiological mechanism why VS may undergo clinically evident ITH while other histologically benign tumors rarely show this phenomenon remains unclear. Some theories include arterial tumor invasion, microvascular proliferation of thin-walled tumor arterial feeders lacking tunica media, and necrosis due to uncontrolled tumor growth.



**Figure 4.** Inner ear anatomy with VS

Intratumoral hemorrhage causes a 10% increase in mortality. Large tumor size (>2 cm) and rapid tumor growth are two suspected etiologies of ITH, and rapid tumor expansion may result from ITH. Factors such as hypertension, and heavy physical activity are mentioned as risk factors for ITH in VS. An association between hypertension control and the risk of intratumoral hemorrhage in patients with VS has been reported.<sup>6</sup>

Most VS are treated with surgical resection or stereotactic radiosurgery. Several articles reveal an association between intratumoral hemorrhage and cystic VS. Moreover, cystic VS has the potential to cause sudden neurological deterioration and deficits. It appears that cystic VS presents with sudden, irreversible neurological deficits with greater frequency than regular VS.<sup>7</sup>

Based on experience, VS that grows at a rate of 1 to 2 mm per year may be more susceptible to bleeding. Surgery is recommended in this type of tumor because intratumoral hemorrhage can cause nerve deficits due to mass effect on the nerve. For example, in cases with significant intratumoral hemorrhage, cranial nerve VIII dysfunction was seen in 46.9% of all cases.

VS is considered rare. Every year, about one in every 100,000 people experiences a VS. The incidence of unilateral VS (one side) represents approximately 8% of all cases of tumors in the skull. Anyone can develop acoustic neuroma, some populations are at higher risk. The incidence occurs more frequently with increasing age, with a peak in those aged 65 to 75 years. Acoustic neuroma is very rare in children. The prevalence is the same between men and women. Asians have the highest incidence, followed by whites, and then blacks.<sup>8</sup>

Due to compression of the vestibulocochlear nerve, the most common manifestations of this tumor are classified into tinnitus, vertigo, disequilibrium, and unilateral sensorineural deafness. Bleeding associated with VS is rare historically described in less than 1% of cases. Rapid expansion of the tumor due to intratumoral hemorrhage is associated with acute onset of headache, nausea, vomiting, and facial nervous weakness.<sup>9</sup> Symptoms of VS can resemble those of other ear problems. These similarities make it difficult to diagnose acoustic neuroma.<sup>10</sup> Treatment options generally include, Monitoring: If the tumor is small, not growing rapidly and not causing any symptoms, it may be recommended to monitor the tumor but not actively treat it. Undergo regular MRI scans to watch for tumor growth. If

it grows or causes symptoms, you can immediately turn to active treatment.

**Radiosurgery:** For small and medium sized tumors, this approach can stop tumor growth. The patient received a single high-dose targeted radiation therapy directly to the tumor. This approach limits the amount of radiation that affects surrounding healthy tissue. Patients will need ongoing scans during treatment to spot tumor growth.

**Microsurgery:** this type of surgery uses instruments designed to operate on small, sensitive areas. The goal is to remove as much of the acoustic neuroma as possible while preserving facial nerve function. Surgery is the only treatment option that can remove the tumor permanently. In some cases, the surgeon can maintain the patient's hearing function so that it remains functioning properly. The smaller the tumor, the greater the chance that it can be removed and hearing is maintained well.<sup>11</sup>

Complications include cerebrospinal fluid (CSF) leak, ataxia, tinnitus, facial numbness, taste disorders, lower cranial nerve deficits, post-operative bleeding, brain edema, meningitis etc. In this study, the incidence of CSF leak was lower than literature reports. Only 18 cases (2.7%) experienced CSF leak. However, CSF leak is a common complication with an incidence of 6,2–20% following resection of large VS, characterized by otorrhea, rhinorrhea and incisional CSF leak. Sughrue et al. believe the most common factor for CSF leak is associated with the surgical approach. It is not true that larger tumors are more susceptible to CSF leakage. In contrast, the trans-labyrinthine approach is more likely to cause CSF leak than the trans-retrosigmoid approach.<sup>12</sup>

The choice of surgical procedure is made based on tumor size, tumor extent within the canal, surgeon preference, and basic hearing function. The most commonly used approach is the retrosigmoid (RS) or sub-occipital approach. This approach allows for hearing preservation while providing adequate exposure. Disadvantages of RS include CSF leak, headache, cerebellar retraction, and a higher risk of tumor recurrence due to limited ability to remove the intracanalicular portion of the tumor. However, a combined endoscopic / microscopic approach may improve access to deep lesions.<sup>13</sup>

Close monitoring of neurological function in the ICU after surgical removal of a VS is common in all patients; however, the need for extended care in the ICU varies greatly. Various factors can lead to increased length of stay (LOS) in the ICU including variability in preoperative, intraoperative, and postoperative management. Coordinated care with a multidisciplinary approach has been shown to be effective in reducing overall LOS in patients treated for VS.<sup>5</sup>

Some of the most common complications after radiosurgery are cranial neuropathy, hydrocephalus, and brain stem / cerebellar injury. Complications after surgery include headache, bleeding, stroke, blood vessel injury, infection, cranial nerve injury, tumor recurrence, CSF leak, and death. Conventional surgical complications involving cranial nerve dysfunction are caused by lesions of the facial, trigeminal, and vestibulocochlear nerves. Approximately 10% of cases of trigeminal neuralgia have been associated with secondary CPA tumors.<sup>14</sup>

In general, postoperative complications for typical VS include sensorineural hearing loss (>60%), facial nerve paralysis (<10%), surgical site bleeding (<3%), and meningitis (<2%). In a study conducted by Woo et al, two patients had worse sensorineural hearing loss, while the remaining patient had no damage. Although the patients required subsequent reoperation for evacuation of the hematoma, the long-term postoperative functional performance for all three patients was satisfactory. Including the current case, 19 (43%, 19/44) ITH VS patients experienced postoperative hearing loss and 22 (50%, 22/44) experienced facial nerve paralysis which is much higher than the frequency of procedure-related complications for nonhemorrhagic VS.<sup>15</sup>

Ventilatory management in these patients is important. Because in most cases of neurosurgical operations, mechanical ventilation support is required to ensure that the patient's breathing can be maintained properly. In this case, the patient's breathing was stable and there was no oxygenation disturbance.

Mechanical ventilation uses a low tidal volume strategy. The tidal volume given is 6-8 mL/kgBB. Target PaO<sub>2</sub> value 83-108 mmHg (SpO<sub>2</sub> 95%-100%) and pH 7.35-7.45. Initial setting for mechanical ventilation with PSIMV, PC 10, RR 15, PS 10, PEEP 5, FiO<sub>2</sub> 50%. From these settings, the tidal volume is around 450-550 and saturation is around 97% - 100%.

Observation and regulation of blood sugar in this patient was also carried out using Novorapid insulin therapy with a dose adjusted to the current blood sugar condition. So that during treatment in the



ICU, this patient's blood sugar can be controlled within normal limits.

Blood pressure monitoring and regulation is also carried out from the first time the patient is admitted to the ICU by administering anti-hypertension drugs, namely Amlodipine and Candesartan, with the aim to avoid an increase in intracranial pressure. And during treatment in the ICU, the patient's blood pressure can be maintained within normal limits or there is a slight increase that can still be tolerated.

Supportive care therapy is very important and helpful in the recovery process for post-neurosurgical patients. Hemodynamics are maintained by providing fluid balance according to the patient's clinical condition. In this patient, maintenance fluid was given with 0.9% NaCl. Nutrition is provided with high calories high protein liquid diet via nasogastric tube with an estimated calorie requirement of 3 x the patient's body weight via enteral route. In this case, it is estimated that the patient's calorie needs are ~2100 kcal per day.

The patient was treated for 4 days in the ICU with therapy progressing as expected. In this case, supportive measures such as mechanical ventilation, blood sugar control and blood pressure control are appropriate steps. On the 2<sup>nd</sup> day the patient's clinical condition improved and extubation was carried out. Then, on the 3<sup>rd</sup> day of treatment, the patient was transferred to the HCU. This results match with research by Almosnino et al., 2021 that conclude patients with brainstem compression had significantly longer mean LOS than patients without (1.96 vs 2.53 days,  $P < .0001$ ).<sup>16</sup> Other research by Yawn et al., 2021 conclude the ICU LOS for VS patients was improved in the

postimplementation group with multidisciplinary team versus the preimplementation group.<sup>17</sup> When the follow-up was carried out at the HCU, it was found that the patient was fully conscious without any complaints as felt when she first entered the hospital.

### CONCLUSION

Patients with brainstem compression had significantly longer mean LOS than patients without. We recommend early diagnosis and treatment for these patients, especially people with headaches, vomiting, and sudden hearing loss. We concluded that our cases provide a valuable experience in the latest acceptable time frame for the operation to prevent irreversible neurological impairment. This case explore the potential benefits of a multidisciplinary approach to treatment and surgical intervention for VS.

Post-operative management was carried out on the patient Mrs. S, Female, Age 53 years. This patient also has comorbid such as hypertension with blood pressure which tends to be high during treatment and after surgery. So this patient was given additional therapy with Candesartan 16 mg and Amlodipine 10 mg during treatment in the ICU. This patient also has diabetes mellitus type 2 which has been treated with Metformin 500 mg 3x1. However, after surgery, there was an increase in blood glucose starting from H+1. So therapy was carried out by administering insulin with Novorapid 6-6-6 to ensure the blood glucose level within the normal limits.

This patient's nutritional needs were met by administering high calories high protein liquid diet via nasogastric tube starting with a dose of 6x150 cc which was increased gradually until 6x250 cc for postoperative recovery nutrition.

Hemodynamic monitoring was carried out strictly considering that the tumor was a hypervascular type which had a risk of re-bleeding post-operatively after subtotal resection.

Postoperative therapy is more about supportive treatment by maintaining the airway, regulating blood sugar, blood pressure and providing mechanical ventilation to maintain adequate oxygenation.

## REFERENCES

1. Jackson C, Creighton FX. Acoustic Neuroma (Vestibular Schwannoma). John Hopkins Medicine. 2023.
2. Ostrom QT, Gittleman, H., Fulop, J., Liu, M., Blanda, R., Kromer, C., Wolinsky, Y., Kruchko, C., Sloan, JSB. CBTRUS statistical report: primary brain and central nervous system tumors diagnosed in the United States in 2008–2012. *Neuro Oncol.* 2015;17 Suppl 4 (Suppl 4): iv1-iv62.
3. Lak, Asad M. Yusuf S Khan. Cerebellopontine Angle Cancer. StatPearls. Treasure Island (FL): StatPearls Publishing; 2023 Jan.
4. Niknafs YS, Wang AC, Than KD, Etame AB, Thompson BG, Sullivan SE. Hemorrhagic vestibular schwannoma: review of the literature. *World Neurosurg.* 2014;82(5):751-6. doi: 10.1016/j.wneu.2013.02.069.
5. Yang X, Liu J, Zhang Y, Richard SA. Tumor-associated hemorrhage in patients with vestibular schwannoma. *Acta Neurochir (Wien).* 2018;160(8):1563-9.
6. Mathkour M, Helbig B, McCormack E, Amenta PS. Acute presentation of vestibular schwannoma secondary to intratumoral hemorrhage: A case report and literature review. *World Neurosurg.* 2019;129:157–63.
7. Moscovici S, Limb R, Azriel A, Briggs R, Hall N, Kaye AH. Repeated spontaneous intratumoural and subarachnoid haemorrhage in an anticoagulated patient with a previously-irradiated vestibular schwannoma: Case report. *J Clin Neurosci.* 2020;73:323–5.
8. Lin D, Hegarty JL, Fischbein NJ, Jackler RK. The prevalence of “incidental” acoustic neuroma. *Arch Otolaryngol Neck Surg.* 2005;131(3):241-244.
9. Hatam J, Mokhtari M, Ahmadi SA, Bahrami E, Mirsalehi M, Mohebbi S, et al. Acute hemifacial and hemiparesis caused by hemorrhagic vestibular schwannoma; A case report. *Clin Neurosci J.* 2022;9:e6.
10. Lee SH, Choi, SK., Lim, YJ., Chung, HY., Yeo, JH., Na, SY., Kim, SH., Yeo, SG. Otologic manifestations of acoustic neuroma. *Acta Otolaryngol.* 2015. 135(2):140-6
11. Leon J, Trifiletti, DM., Waddle, MR., Vallow, L., Ko, S., May, B., Tzou, K., Garcia, HR., Lundy, L., Chaichana, K., Vibhute, P., Peterson, JL. Trends of the initial management of vestibular schwannoma in the United States. *J Clin Neurosci.* 2019;68:174-178.
12. Huang MY, Vermeulen S. Clinical perspectives regarding patients with internal auditory canal or cerebellopontine angle lesions: surgical and radiation oncology perspectives. *Semin Ultrasound CT MR.* 2003 Jun;24(3):124-32.

13. Huang, X., Xu, J., Xu, M., Chen, M., Ji, K., Ren, J., Zhong, P. Functional outcome and complications after the microsurgical removal of giant vestibular schwannomas via the retrosigmoid approach: a retrospective review of 16-year experience in a single hospital. *BMC Neurol* 17, 18 (2017).
14. Springborg JB, Poulsgaard L, Thomsen J. Nonvestibular schwannoma tumors in the cerebellopontine angle: a structured approach and management guidelines. *Skull Base*. 2008 Jul;18(4):217-27.
15. Woo PY, Lam PL, Ip YH, Chan TS, Ng OK, Kwan MC, Wong HT, Wong AK, Chan KY. "When the Benign Bleed" Vestibular Schwannomas with Clinically Significant Intratumoral Hemorrhage: A Case Series and Review of the Literature. *Asian J Neurosurg*. 2021 Feb 23;16(1):221-227.
16. Almosnino G, Sikora MJ, Farrokhi FR, Schwartz SR, Zeitler DM. Tumor-Related and Patient-Related Variables Affecting Length of Hospital Stay Following Vestibular Schwannoma Microsurgery. *Ann Otol Rhinol Laryngol*. 2022 May;131(5):535-543.
17. Yawn RJ, Nassiri AM, Harris JE, Manzoor NF, Godil S, Haynes DS, Bennett ML, Weaver SM. Reducing ICU Length of Stay: The Impact of a Multidisciplinary Perioperative Pathway in Vestibular Schwannoma. *J Neurol Surg B Skull Base*. 2021 Feb 4;83(Suppl 2):e7-e14.